

Significant reduction in radiation levels with excellent image quality

Philips AlluraClarity system in Pediatric Cardiology Interventions

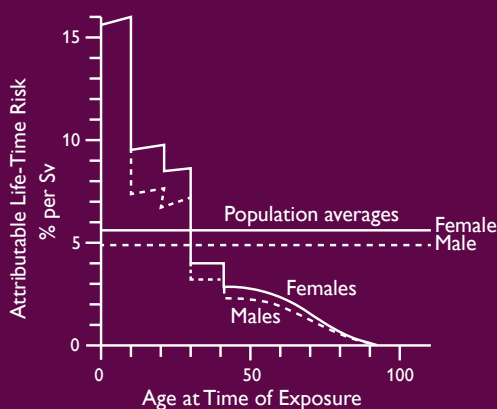


Figure 1: Attributable life time risk due to 1 Sv of radiation versus age at time of exposure. The figure¹ was adapted from International Commission on Radiological Protection (ICRP) Publication 60²

The benefits that medical imaging brings to children and adults in the diagnosis and treatment of many medical conditions are recognized worldwide. Unfortunately, these imaging modalities use ionizing radiation that has been proven to cause damage to DNA and increase the chance of developing cancer. In fact, pediatric populations have a greater lifetime risk of developing radiation-induced cancers than adult patients¹, and the lifetime attributable risk of a radiation-induced cancer from 1 Sv of dose during the first decade of life in a child is about 15% (Figure 1).

1. BEIR 2006. Health Risks From Exposure to Low Levels of Ionizing Radiation: BEIR VII. Washington, DC: National Academic Press; 2006.
2. ICRP. 1991.1990 Recommendations of the International Commission on Radiological Protection. ICRP Publication 60. Ann. ICRP 21 (1-3)

AlluraClarity in Pediatric Cardiology Interventions

The latest generation of Philips cathlab systems, the AlluraClarity family with ClarityIQ technology, is able to break from the standard relationship between image quality and radiation dose, thus achieving a dramatic reduction in X-ray dose, while maintaining an equivalent image quality. Hereby, setting a new standard in the equipment related dose.

The unique ClarityIQ technology touches every part of the AlluraClarity system from X-ray generation to display. The combination of advanced, complex image processing and flexible digital imaging pipeline allowed a completely redefinition and fine-tuning of more than 500 parameters to reduce radiation dose and optimize image quality for each clinical application.

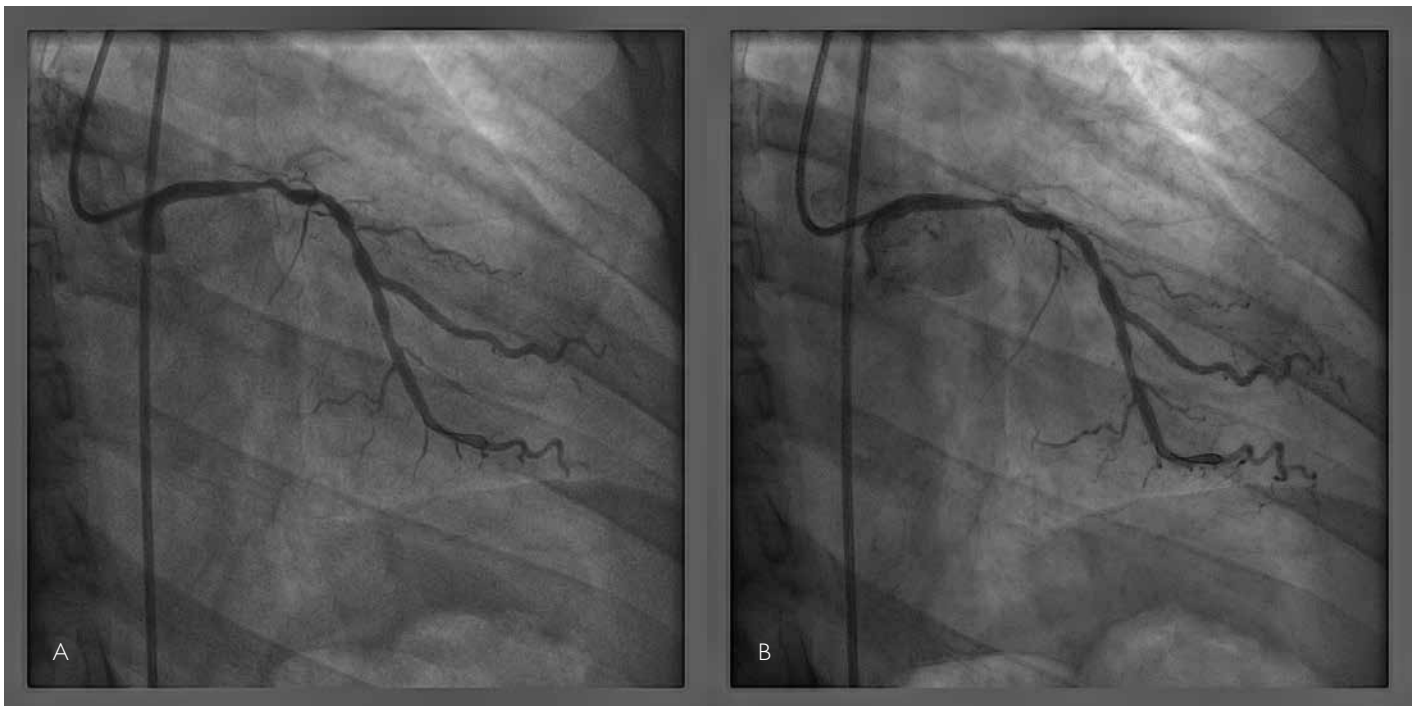


Figure 2: Both images were acquired on the same patient at the same c-arm projection and procedure; A) acquisition run was acquired with Allura Xper default setting and image B) was acquired with AlluraClarity default setting where dose setting is 50% lower. Image courtesy: prof. dr. N. Reifart, Main-Taunus Cardiac Center, Bad Soden, Germany



The cases and images are courtesy from University Children's Hospital, Zurich, Switzerland, Prof. Dr. Oliver Kretschmar.

In adult coronary angiography, (Figure 2) demonstrates the image quality of an exposure with the Allura Xper and an exposure with the AlluraClarity setting, exposing the patient to 50% of the original dose. Whereas similar comparative images cannot be acquired in the vulnerable pediatric population, the following two clinical cases demonstrate the radiation exposure benefits of the AlluraClarity FD10/10 cathlab system in CHD.

Note the low DAP (Dose Area Product) and AK (Air Kerma) values of each of the runs and also the image quality in both exposure and fluoroscopy runs.

Case #1

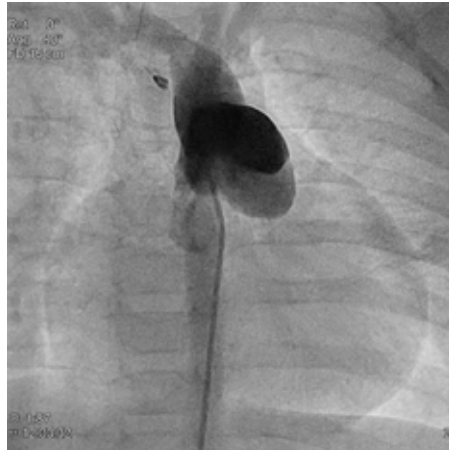Interventional balloon-dilation of a residual aortic coarctation after Norwood stage II procedure



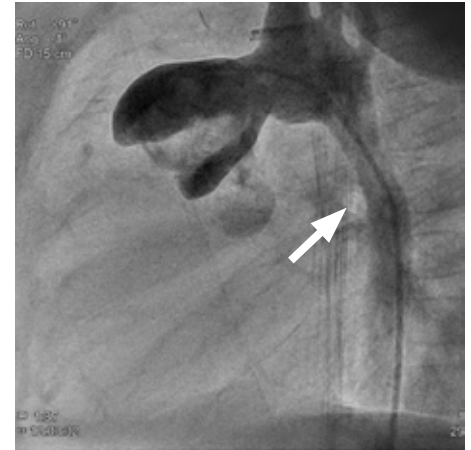
Patient history

The patient was an 11 months old female with hypoplastic left heart syndrome (HLHS) and an atrioventricular septum defect. She had undergone the stage I Norwood procedure at 2 months and the stage II procedure with bidirectional cavopulmonary anastomosis at 6 months. Surgical scars can induce significant aortic coarctation which was the case in this patient.

There was a pressure gradient of 25 mmHg across the coarctation, which needs to be addressed in a functionally single ventricle heart malformation. The patient was admitted by the Department of Pediatric Cardiology at University Children's Hospital Zurich (Switzerland) for elective balloon aortoplasty.

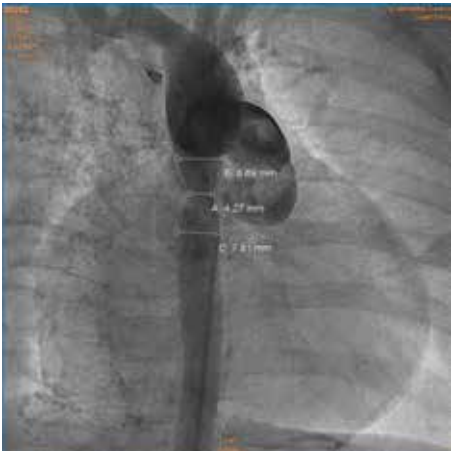

LAO 0 Caudal 0, 15 fps
Field of view: 15 cm



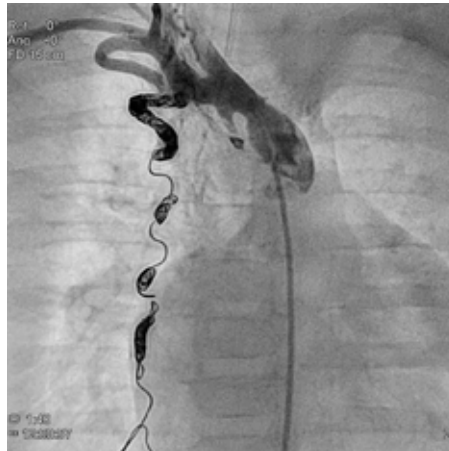LAO 91 Cranial 1, 15 fps
Field of view: 15 cm

Angiography image from the biplane system demonstrating the coarctation in the aorta (arrow)



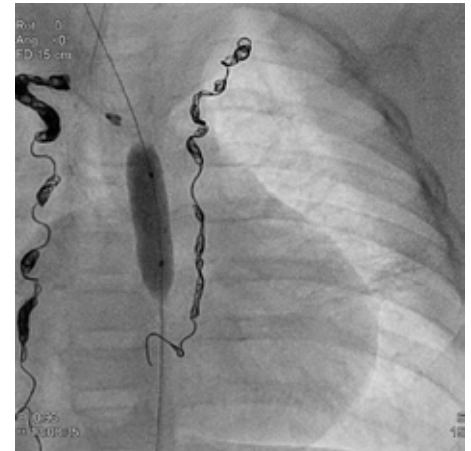
LAO 0 Caudal 0, 15 fps
Field of view: 15 cm

Measurement of the coarctation revealed a constriction in the diameter of 4.27 mm. Pre-interventional systolic gradient across the coarctation was 25 mmHg.



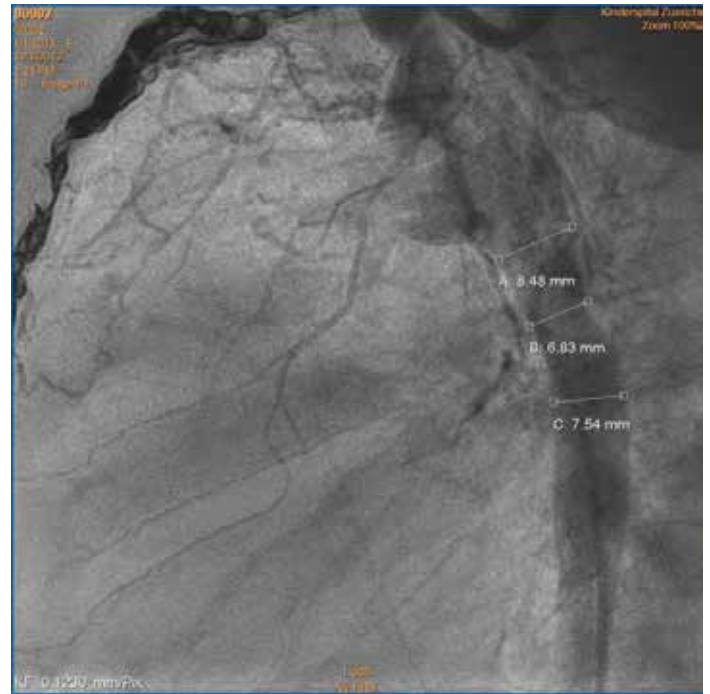
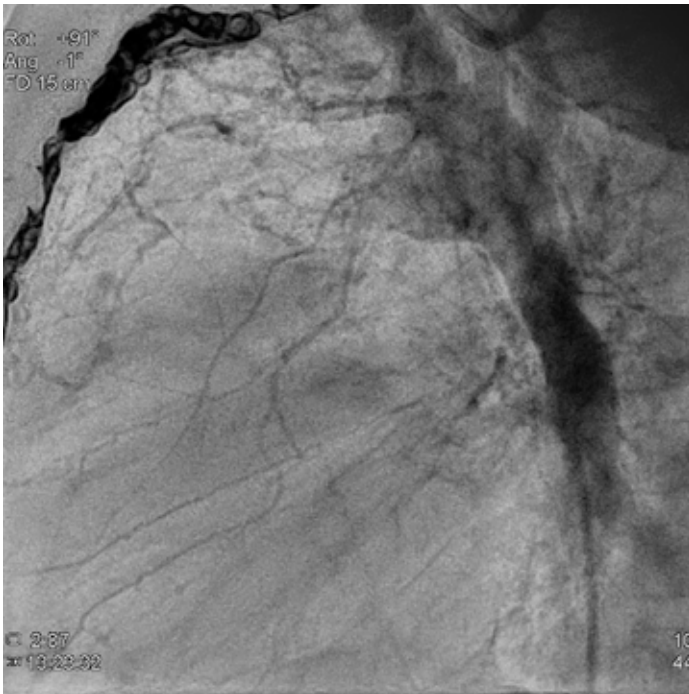
LAO 0 Caudal 0, 15 fps
Field of view: 15 cm

The diagnostic angiograms also revealed diffuse bilateral aortopulmonary collaterals (MAPCAs) arising from the internal mammary arteries, possibly due to the pressure overload of the coarctation. During the procedure these collaterals/mammary arteries were coil occluded. Post interventional angiography demonstrates the closed right internal mammary artery.



LAO 0 Caudal 0, 15 fps
Field of view: 15 cm

The coarctation was then dilated with 8 mm and 10 mm balloons.



Result after dilation of the coarctation. The result was satisfying with an aortic diameter at the level of the coarctation of almost 7 mm and insignificant residual systolic pressure gradient (2 mmHg). LAO 91 Cranial 1, 15 fps, Field of view: 15 cm

Dose report

Fluoro time [mm:ss]	12:46
Acquired exposure runs [N]	10
Exposure images [N]	1034
Cumulative Frontal Air Kerma [mGy]	13
Cumulative Lateral Air Kerma [mGy]	8
Cumulative DAP (fluoro) [mGycm ²]	780
Cumulative DAP (exposure) [mGycm ²]	294
Total Cumulative DAP [mGycm ²]	1074

Conclusion and final results

Post Norwood procedure coarctation of the aorta can occur. This patient was suffering from an univentricular heart syndrome. Therefore, the coarctation in this patient was unacceptable due to the long term prognosis of the patient regarding progressive hypertension and the potential of heart failure. After coil occlusion of several aortopulmonary collaterals, retrograde balloon angioplasty of the coarctation was performed and eliminated the gradient. As this child may require further intervention in the future, reducing radiation is of critical importance. The total cumulative DAP achieved in this clinical situation was 1074mGycm² with a frame rate of 15 fps. The whole procedure lasted 60 minutes.

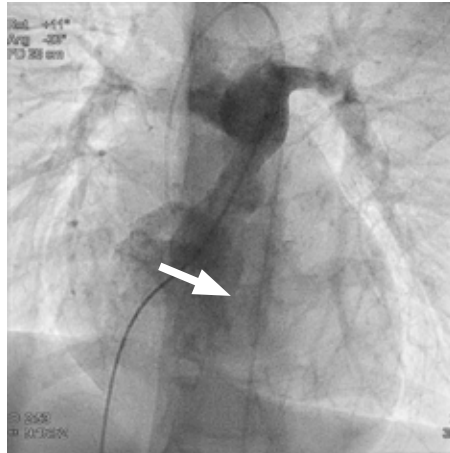
Case #2

Restenosis of the pulmonary valve in a ten year old

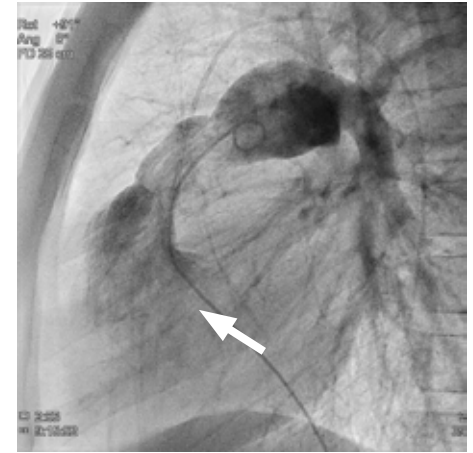


Patient history

A 10 year old boy with history of a highgrade aortic valve stenosis had received a Ross Konno operation with implantation of a 16mm Contegraft in pulmonary artery position at the age of 7 months. He now presented with severe pulmonary valve stenosis and moderate insufficiency and decreased physical fitness (systemic pressure 86/39 mmHg). He had previously received repeat balloon valvuloplasties at 15 and 33 months. Preceding MRI examination confirmed and visualized the alterations of the Contegra graft. During diagnostic catheterization® (under general anesthesia) a pressure gradient of 25 mmHg was measured, the right ventricle was enlarged and hypertrophic. The intended treatment modality was a percutaneous pulmonary valve replacement with a Melody™ valve.

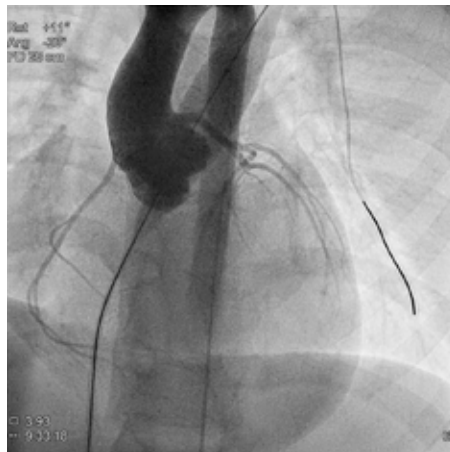

LAO 11 Cranial 23, 15 fps
Field of view: 25 cm

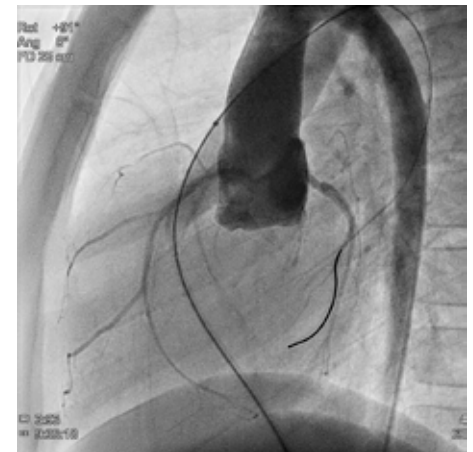


LAO 91 Cranial 0, 15 fps
Field of view: 25 cm

Angiogram demonstrating the stenosis within the pulmonary valve (arrows). Measurements revealed a minimal diameter of 12-13mm measured in the mid 1/3 of the graft, and a distal diameter of 18-20mm just before the pulmonary bifurcation.

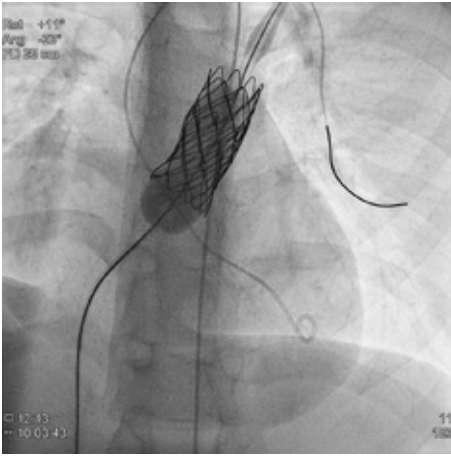


LAO 11 Cranial 23, 15 fps
Field of view: 25 cm



LAO 91 Cranial 0, 15 fps
Field of view: 25 cm

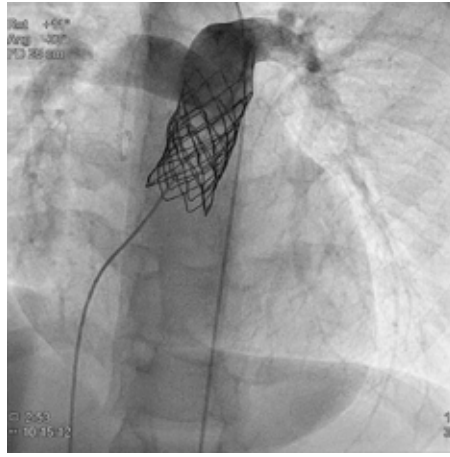
Exclusion of coronary compression as a possible contraindication for Melody™ valve implantation was achieved via simultaneous balloon dilatation of the pulmonary graft (18mm, Atlas balloon™) and aortic injection.



LAO 11 Cranial 23, 15 fps

Field of view: 25 cm

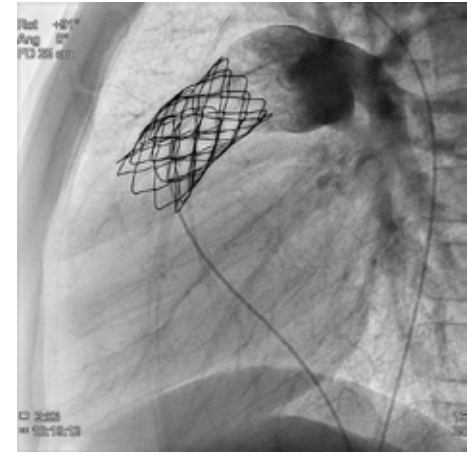
Pre-stenting of the pulmonary graft was done with a 39 mm CP Stent™ on a 18 mm BiB balloon™.



LAO 11 Cranial 23, 15 fps

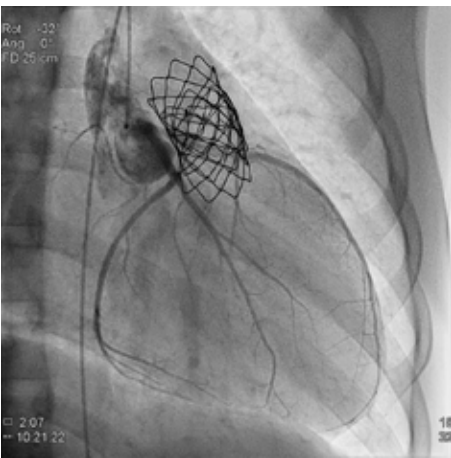
Field of view: 25 cm

The Melody™ valve was placed with an external balloon diameter of 20mm. Postdilatation of the valve was performed using a 20 mm high pressure Atlas balloon™ with fluoroscopy (not shown). Post valve placement there was no significant pulmonary valve insufficiency, no residual pressure gradient, and the vessel wall was regular and free of any dissection.



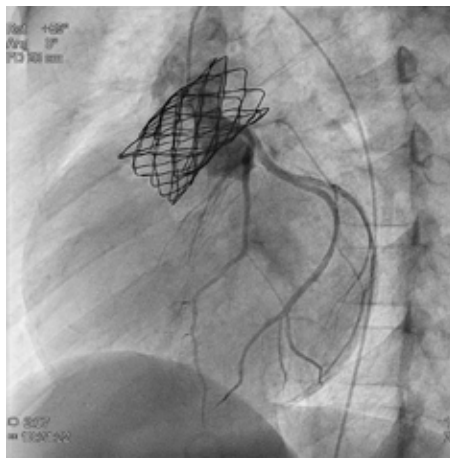
LAO 91 Cranial 0, 15 fps

Field of view: 25 cm



LAO 91 Cranial 0, 15 fps

Field of view: 25 cm



LAO 91 Cranial 0, 15 fps

Field of view: 25 cm

A final exposure run was made to exclude any compression of the left coronary artery using a selective injection. The images demonstrate patent left coronary artery.

Dose report

Fluoro time [mm:ss]	14:41
Acquired exposure runs [N]	18
Exposure images [N]	3150
Cumulative Frontal Air Kerma [mGy]	36
Cumulative Lateral Air Kerma [mGy]	36
Cumulative DAP (fluoro) [mGycm ²]	2924
Cumulative DAP (exposure) [mGycm ²]	5387
Total Cumulative DAP [mGycm ²]	8311

Conclusion and final results

The patient described in this case was suffering from severe pulmonary graft stenosis and moderate insufficiency. During the procedure time of 85 minutes a Melody™ valve was placed into this failing graft while exposing the patient to 8311 mGycm² with 15 fps. This intervention replaced a surgical valve replacement and hopefully provides the patient with enough capacity to stay out of the OR for the rest of his childhood.

Conclusion

The new AlluraClarity with ClarityIQ technology generates equivalent image quality at 50% less dose.

"As the treating and responsible physician it's our obligation towards our small (and vulnerable) patients to use the newest and highly developed available technology".

"Especially for pediatric patients it's extremely important to achieve the lowest radiation dosage, conserving at the same time the best required imaging quality, which is necessary to perform safe and successful interventional procedures in this specific patient population".

"Our experience with AlluraClarity is that we are able to obtain 50-75 % dose reduction³ compared to the previous generation X-ray systems – even with “extra low dose” (lowest fluoroscopy settings) we are able to depict the shape of the heart and the vessels sharply and correctly”

"Our patients often need to undergo repeated multiple complex interventional procedures with an accumulation of dosage; therefore, it is extremely important to work with the lowest dose obtainable."




Prof. Dr. Oliver Kretschmar

³ The dose reduction findings are consistent with the range of AlluraClarity dose settings tested at Kinderspital Hospital in Zurich (DHF 174220)

The new AlluraClarity with ClarityIQ technology provides equivalent image quality at 50% less dose. This provides the flexibility to use the system in a personalized way for each procedure and patient. It is now possible for example to use lower frame rates, fluoroscopic angiograms, and just rely on the lower default exposure and

fluoroscopy settings, to reduce the total patient radiation without compromising image quality and patient care. In congenital heart disease interventions, this breakthrough alleviates some of the concern over repeat radiation in a particularly vulnerable population.



Not for distribution in the USA

© 2013 Koninklijke Philips N.V. All rights are reserved.
Philips Healthcare is part of Royal Philips

Philips Healthcare reserves the right to make changes in specifications and/or to discontinue any product at any time without notice or obligation and will not be liable for any consequences resulting from the use of this publication.

Printed in The Netherlands.
4522 962 97691 * OCT 2013

How to reach us
www.philips.com/healthcare
healthcare@philips.com

Product information
www.philips.com/AlluraClarity